

Augmentation of Wound Healing Using Monochromatic Infrared Energy

Exploration of a New Technology for Wound Management

Lon R. Horwitz, DPM, CWS; Thomas J. Burke, PhD; and Dale Carnegie, DPM

Abstract

The results presented in this paper document healing of different types of extremity wounds with 890 nanometer (nm) monochromatic infrared energy. Recalcitrant dermal lesions, including venous ulcers, diabetic ulcers, and a wound related to scleroderma, were treated with a Food and Drug Administration-cleared infrared device. The infrared protocol was instituted after conventional management protocols were shown to be ineffective. The rate and quality of healing of these previously refractory wounds, following use of monochromatic infrared energy, may be related to local increases in nitric oxide concentration. Increases in nitric oxide previously have been demonstrated to correlate with vasodilatory and anabolic responses. Further research is needed to confirm the results found in these patients.

ADV WOUND CARE 1999; 12:35-40

VENOUS ULCERS, DIABETIC ULCERS, AND postamputation wounds are difficult to manage and often do not heal, even with aggressive medical management and conscientious patient compliance. The lack of consistent and favorable outcomes is a costly problem for the health care industry, patients, and physicians. With an aging American population, the opportunity to explore novel and cost-effective treatment strategies will likely increase during the next several decades.

It has recently been demonstrated that a commercially available, Food and Drug Administration-cleared monochromatic

infrared energy (MIRE) modality increases nitric oxide (NO) in the blood and plasmas of normal adult subjects (authors' unpublished research). An elevation in NO has been suggested to be the basis of improved rates and quality of healing during L-arginine or nitroglycerin therapy in patients with wounds.¹⁻³ Dietary L-arginine, a source of NO via the constitutive isoform of the enzyme nitric oxide synthase (cNOS), increases the rate of wound healing following traumatic, thermal, and fracture injuries.⁴⁻⁶

It has been proposed that through this NO-mediated process, MIRE might prove beneficial in patients with venous and diabetic ulcers and in patients who exhibit slow rates of postamputation wound closure. The authors have evaluated the efficacy of wound healing during use of a commercially available MIRE device. The 5 patients discussed in this paper had wounds that were deteriorating or stagnant.

Purpose

The authors propose that the net result of increasing local amounts of circulating NO may be neovascularization, enhanced tissue perfusion, and successful wound healing.

Lon R. Horwitz, DPM, CWS, is on the teaching faculty and attending staff, Department of Surgery, Podiatric Section, at the Denver Veterans Affairs Medical Center, Denver, CO. Thomas J. Burke, PhD, is Associate Professor of Medicine, Department of Medicine, at the University of Colorado Medical School, Denver, CO, and President, Integrated Systems Physiology, Aurora, CO. Dale Carnegie, DPM, is a staff podiatrist in the Department of Orthopaedics, Podiatry Section, at Denver Health Medical Center, Denver, CO. The monochromatic infrared light used in this study was supplied by Anodyne Therapeutics, Denver, CO. Submitted August 28, 1998; accepted in revised form October 21, 1998.

Protocol

Approval for this protocol was obtained from the Colorado Multiple Institutional Review Board (COMIRB) prior to subject recruitment at the Denver Veterans Affairs Medical Center (DVAMC) and Denver Health Medical Center (DHMC) in Denver, CO. Subjects were recruited from patients attending the weekly DVAMC podiatric medical clinic or the DHMC physical medicine clinic. All had undergone months or years of conventional wound management (ie, alginate dressing [SORBASAN], a collagen gel [Kollagen], Unna's paste boot, silver sulfadiazine cream [Silvadene], wet-to-moist dressings, compression wraps), with little or no improvement in signs and symptoms, before initiation of the MIRE protocol.

Subjects with venous ulcers were recruited by one of the authors (L.R.H.) from the DVAMC clinic. They were given instructions on how to use the MIRE device at home. Subjects were to discontinue their previous conventional modalities, use the MIRE device for 30 minutes each day, redress the wound with a sterile saline wet-to-moist gauze dressing, apply a compressive elastic wrap, and return to the DVAMC podiatric clinic 1 week later. Each clinic visit was marked by thorough topical wound debridement and redressing with a wet-to-moist dressing, followed by application of a compressive elastic wrap around the wound and the lower extremity involved. Subjects were then seen twice a month or monthly for the next several months, depending on wound severity and progress toward healing. Wounds were photographed with a 35 mm camera. The photographs were scanned into a computer, and a commercially available image measurement and statistical software program was used to calculate the wound surface in square centimeters. The software can calculate area, perimeter, radius, and other measurements based on the ruler in the photograph.

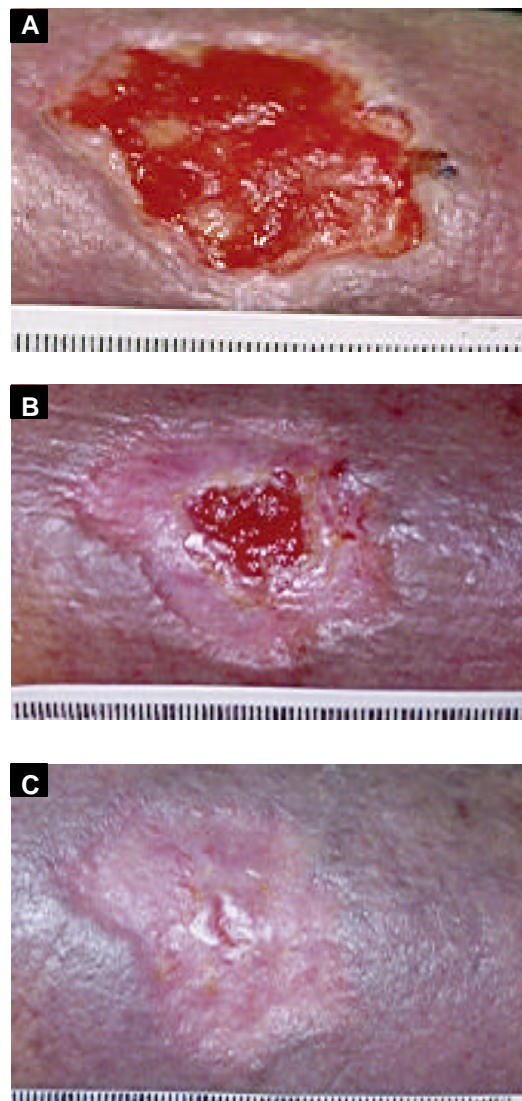
Subjects with ulcerations related to dia-

betes were recruited by one of the authors (D.C.) from the DHMC clinic. Their wounds were more recent or postsurgical in nature. Each clinic visit was marked by thorough topical wound debridement, a 30-minute treatment with the MIRE device, and redressing with a wet-to-moist gauze dressing. Patients were seen in the DHMC clinic weekly, then progressing to 2- to 3-week intervals, depending on wound severity and evidence of healing. Wounds were photographed with a 35 mm camera. As with the venous ulcers, the photographs were scanned into a computer and the wound surface area was calculated in square centimeters.

The author at the University of Colorado Medical School (T.J.B.) recruited the subject with a wound related to scleroderma. This subject was assessed and given a MIRE device for home use, with clinic visits scheduled every other week to monitor progress.

The MIRE device was cleared by the Food and Drug Administration in 1994 for the purpose of enhancing circulation and reducing pain. It delivers MIRE at 890 nanometers (nm) wave length (the only wave length the MIRE device emits) from each of 2 flexible pads containing 60 Gallium Aluminum Arsenide (GaAlAs) diodes. The uniform average power emitted over the pad surface (22.5 cm^2) of the diode array was $9.0 \text{ milliwatts/centimeter squared (mw/cm}^2\text{)}$, as measured with a Centronic OSD60-5T photodiode (Newberry, CA) Total energy density per 30-minute application (for

Figure 1
PROGRESS OF WOUND HEALING
IN SUBJECT 1



Venous ulcer measures 8.29 cm^2 on April 2, 1997 (photo A), 1.21 cm^2 on July 30, 1997 (photo B), and is resolved on October 29, 1997 (photo C).

each pad) was $43.2 \text{ Joules/centimeter squared (Jcm/cm}^2\text{)}$. Of particular interest was the flexible nature of these pads, which allows placement on uneven body surfaces and at more than a single site. The design of the flexible pad allows the

infrared energy to be delivered perpendicular to and in contact with the involved site.

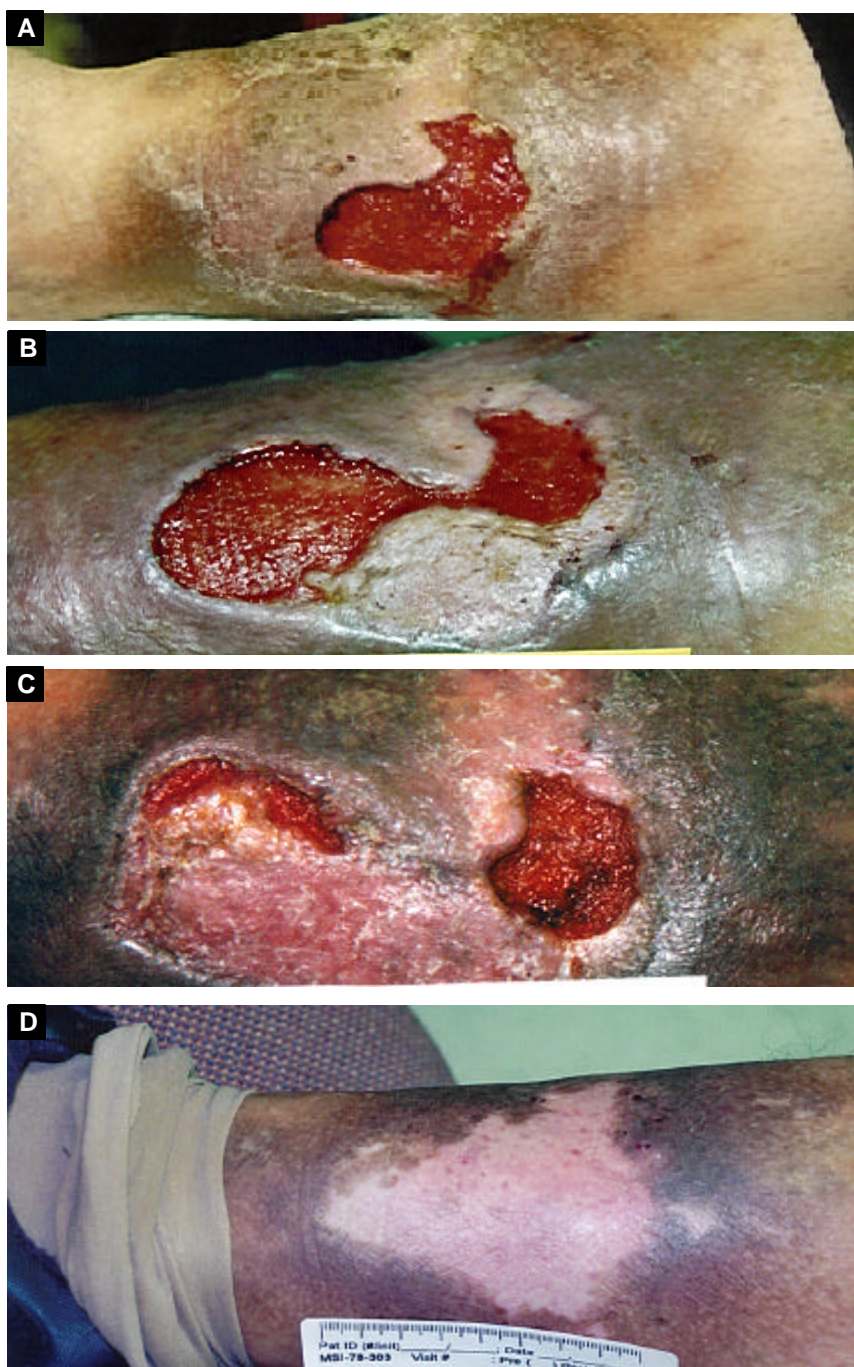
Subject 1

This 60-year-old, nondiabetic, Caucasian male had a painful venous ulcer, which had initially appeared in 1958, on his right lower leg. The subject enrolled in the study on March 12, 1997, after failed therapy with Unna's paste boot, an alginate dressing (SORBSAN), a collagen gel (Kollagen), and compression sock therapy over several weeks. On April 2, 1997, the ulcer's area measured 8.29 cm². The patient's protocol was daily use of the MIRE device at home for 30 minutes per day, after showering and cleaning the ulcer with a mild saline solution, and continued use of compression therapy. On July 30, 1997, the lateral ulcer measured 1.21 cm², and it resolved on October 29, 1997 (Figure 1). As of August 26, 1998, there have been no signs of tissue deterioration. The subject continues to be employed full-time, and he remarried during his study participation due to renewed self-image.

Subject 2

A 64-year-old, nondiabetic, obese, Caucasian male presented with a venous ulcer that had existed for 13 years. The wound was located at the lateral mid-calf on his left leg and was neither deteriorating nor progressing toward healing with conventional modalities (Unna's paste boot, a skin protectant spray [GRANULEX], a hydrocolloid dressing [DuoDERM], and silver sulfadiazine cream [Silvadene]). This subject was provided with an MIRE device for home use. Direct contact application was self-administered for 30 minutes every day prior to wet-to-moist dressing changes. A compression bandage was used for its therapeutic value and its ability to hold the dressings in place. Progress was monitored with weekly clinic visits

Figure 2
PROGRESS OF WOUND HEALING IN SUBJECT 2



Venous ulcer measures 21.34 cm² on October 25, 1995 (photo A), 9.78 cm² on December 6, 1995 (photo B), 1.61 cm² and 3.41 cm² on April 10, 1996 (photo C), and is resolved with no breakdown on May 28, 1998 (photo D).

initially. As the ulcer healed, progress was monitored with monthly clinic visits. The wound area was 21.34 cm² at the initiation of the MIRE protocol on October 25, 1995 (Figure 2).

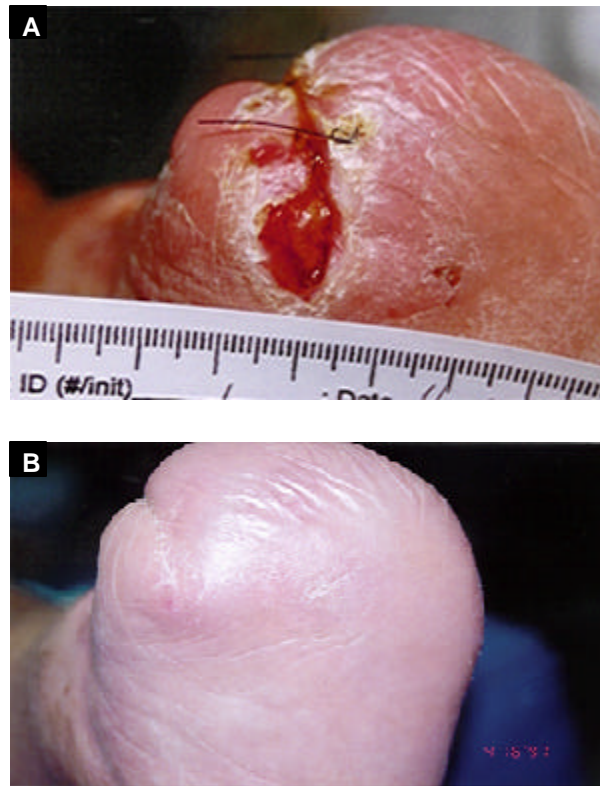
Eleven months later (September 11, 1996), use of the MIRE was discontinued, with the wound area measuring 1.3 cm². Wet-to-moist dressings were applied every day, along with compression wrap therapy, and clinical debridement was performed every 4 weeks. On May 28, 1998, long-term follow-up revealed healthy pink, full-thickness, intact skin, absence of hemosiderin deposition, and no open lesion. Compression sock therapy was instituted for long-term management of lower extremity venous disease. The subject is now employed full-time and has achieved his goal of playing softball.

Results with Diabetic Ulcers

Subject 3

A 64-year-old African American female with Type I diabetes presented with wound dehiscence 2 months after a left great toe amputation. She was assessed and instructed on the use of the MIRE device at home. She began therapy on November 25, 1996. The distal pedal wound was 1.81 cm² (Figure 3), and a 2-year-old dorsal wound (not shown) was 7 cm². The MIRE device was administered for 30 minutes every other day, followed by wet-to-moist dressings, and the subject was monitored with clinic visits at the DHMC every other week. After the first 6 weeks, the interval between clinic visits was extended to 2 to 3 weeks. This subject became weight-bearing on February 12, 1997 - the first

Figure 3
PROGRESS OF DISTAL WOUND HEALING
IN SUBJECT 3



Wound dehiscence measures 1.81 cm² on November 25, 1996 (photo A) and is resolved on April 16, 1997 (photo B).

time in 2 years - and was fitted with an orthotic. Monochromatic infrared energy usage was discontinued after 5 months of management, and complete closure of the distal and dorsal wounds was achieved.

This subject also had a wound on her right heel that had been present for 7 months and was deteriorating with conventional management. After wound debridement, tendon exposure was noted. Outpatient therapy began on October 16, 1996, when the heel ulcer measured 2.26 cm². She used the MIRE device at home, and she was followed with twice-a-month clinic visits. By April 16, 1997, there was no clinical evidence of an open wound.

This subject was able to join her husband on a fishing trip for the first time in 2 years.

Subject 4

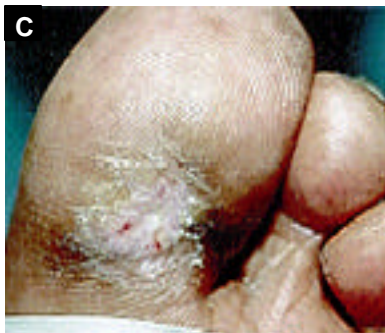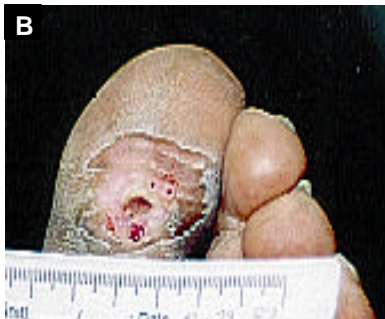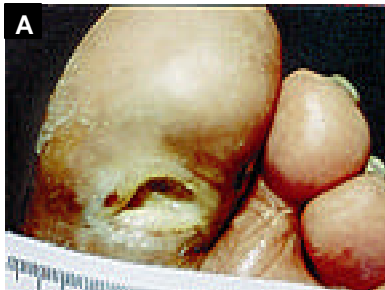This 64-year-old African American male with Type I diabetes presented with a foreign body embedded in his left great toe. The foreign body was surgically excised, and this subject subsequently was discharged. One month later, the subject was referred to the physical medicine clinic at DHMC with a non-healing ulcer, 2 cm in diameter, penetrating down to bone at the surgical site. The subject refused amputation of the left great toe. Treatment involved weekly topical debridement, daily saline soaks with wet-to-moist dressings, and use of the MIRE device for 30 minutes once a week in the outpatient clinic. A transparent dressing (OpSite) was placed over the wound to avoid contamination. A visiting nurse applied a wet-to-moist saline dressing each day. After 3 weeks, sensation in the left great toe returned, edema greatly diminished in the

hallux, and there was noticeable improvement in granulation tissue within the ulcer cavity. During the final 6 weeks, the subject was treated 3 times with the MIRE device. Four months after surgery, the ulcer had healed with neither scarring nor callus tissue (Figure 4).

Results with a Scleroderma-Related Ulcer

A 45-year-old Caucasian female presented with a 13-year history of scleroderma. In November 1997, she developed a painful ulcer on the middle finger of her right hand. Conventional

Figure 4
PROGRESS OF WOUND HEALING
IN SUBJECT 4



Wound area of this diabetic ulcer measures 0.64 cm² on September 3, 1997 (photo A) and 0.18 cm² on October 29, 1997 (photo B). The ulcer is resolved on December 3, 1997 (photo C).

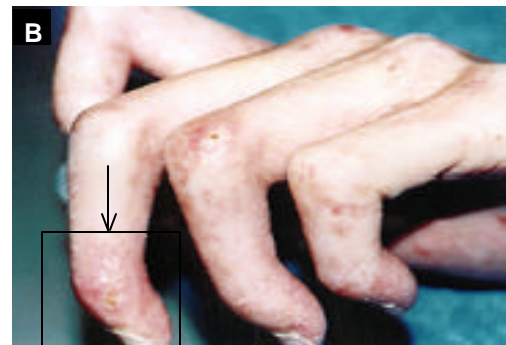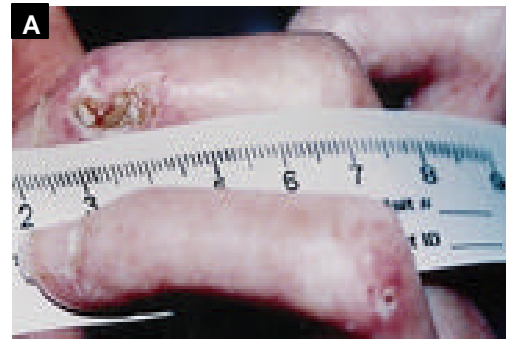therapy yielded no improvement over the next 4 months. At-home MIRE treatments of 30 minutes twice a day began on March 14, 1998. Within 2 weeks, the lesion had completely healed (Figure 5).

Discussion

Monochromatic infrared energy was effective in healing a variety of wounds that either had become stagnant or had deteriorated with conventional management. Because virtually all other interventions were discontinued, these results suggest that MIRE, perhaps the specific wave length of 890 nm, could have been responsible. In addition, the design of the pads that maintained the focused energy density perpendicular to the wound site and the large surface area of the diode array may have contributed to the results achieved. In 3 cases (subjects 1, 2, and 3), the healed wounds have not recurred during 1 to 2 years of follow-up evaluation, despite the cessation of MIRE exposure. The ease of pad placement, which does not involve the stress of continuous hand positioning, is subject-friendly and contributed to the subject compliance required in this study.

It recently has been demonstrated that application of this particular MIRE device to the skin for 30 minutes increases plasma NO in nondiabetic subject volunteers, as measured with a Sievers Instrument, Model 280, Nitric Oxide Detector (authors' unpublished data). NO is a potent endogenous vasodilator that can be liberated from tightly bound hemoglobin on exposure to various wave lengths of energy.⁷ In the patients described here, the use of MIRE on refractory wounds may have involved elevations in local and systemic NO. Recently, Schindl et al⁸ reported increased circulation in the feet of diabetic patients with microangiopathy after using a visible red monochromatic energy device with an energy density of 30 J/cm². The circulatory effects were sustained even after the use of the device was discontinued. Bioavailable NO has been shown to enhance arterial perfu-

Figure 5
PROGRESS OF WOUND HEALING
IN SUBJECT 5



Wound area of this ulcer related to scleroderma measures 0.44 cm² on March 13, 1998 (photo A). The ulcer is resolved on March 27, 1998 (photo B).

sion, by vasodilation, at a site of previous vascular compromise.⁹

NO is a powerful anabolic agent,¹⁰ and it is thought to be the molecule that accounts for the wound healing efficacy of oral supplementation with L-arginine¹ or topical nitroglycerin², both of which are sources of NO. In addition, the healing process may be accelerated by increasing circulatory NO—a potent vasodilator.¹¹ Shorter wave lengths in the ultraviolet range also have been shown to promote vasodilation through release of NO.¹² NO levels were not measured in the subjects described in this paper. However, the enhanced healing suggests that some subjects had the capacity to generate local increases of NO in response to MIRE expo-

sure. It is important to recognize that 2 of the subjects in this DVAMC study had venous ulcers for many years and that no previous therapy had effected wound closure and/or healing. Thus, it is unlikely that the ulcers would have healed without external intervention.

NO is bound to the cysteine 93 of the beta chain of hemoglobin during the passage of red blood cells through the lungs.¹³ In addition to oxygen, hemoglobin also transports NO throughout the body. NO is thought to aid in vascular perfusion by dilatation of arterioles, thus enhancing tissue oxygenation, nutrient delivery, and removal of waste products of metabolism.

MIRE appears to accelerate healing at local sites where the MIRE pad is

placed. This may be accomplished by liberating NO from hemoglobin or possibly from other nitrosylated compounds.¹³ Although NO has a short half-life, usually less than 3 seconds,¹⁴ the body's circulation provides a continuous supply of red blood cells containing NO. Thus, there is an uninterrupted delivery of red blood cells containing NO to the site where the MIRE pads are placed. Once MIRE exposure is initiated, the local effect would be continuous release of NO from hemoglobin, vasodilation, angiogenesis, enhanced tissue perfusion, and less ischemia. There also may be an anabolic effect that manifests itself as improved tissue remodeling.¹⁰

Use of MIRE in the subjects described in this paper appeared to have contributed to improving their quality of life, as described earlier. Enhanced dermal tissue repair and fewer visits to wound care providers potentially allows an overall savings of health care dollars, wound supplies, and physician and patient time. The MIRE device is a novel technology that has been demonstrated to be a noninvasive, portable, drug-free method for potentially healing chronic wounds resistant to conventional modalities.

Additional research is needed to show whether MIRE is independently responsible for wound healing. Originally, the research described in this paper was designed as a COMIRB-approved, randomized, placebo-controlled, double-blind study. However, it soon became apparent to the participating medical professionals which patients were using active versus placebo MIRE devices. For ethical reasons, all patients using the placebo devices were switched to active MIRE devices. **AWC**

References

1. Barbul A. Lazarou AZ. Efron DT. Wasserkrug HL. Efron G. Arginine enhances wound healing and lymphocyte immune responses in humans. *Surgery* 1990; 108:331-6.

2. Gorfine SR. Topical nitroglycerin therapy for anal fissures and ulcers [letter]. *N Engl J Med* 1995; 333:1156-7.
3. Schaffer MR. Tantry U. van Wesep RA. Barbul A. Nitric oxide metabolism in wounds. *J Surg Res* 1997; 71:25-31.
4. Jeevanandam M. Ali MR. Holaday NJ. Weis JK. Peterson SR. Relative nutritional efficacy of arginine and ornithine salts of alpha-ketoisocaproic acid in traumatized rats. *Am J Clin Nutr* 1993; 57:889-96.
5. Haulica I. Busuioac A. Neamtu C. Dorneanu V. Titu G. Spac A. Possible involvement of the L-arginine-nitric oxide pathway in the modulation of stress-induced analgesia. *Functional Neurol* 1995; 10:169-73.
6. Jeevanandam M. Begay CK. Holaday NJ. Petersen SR. Nutritional and metabolic effects and significance of mild orotic aciduria during dietary supplementation with arginine or its organic salts after trauma injury in rats. *Metab Clin Exp* 1997; 46:785-92.
7. Matsunaga K. Furchgott RF. Interactions of light and sodium nitrite in producing relaxation of rabbit aorta. *J Pharmacol Exp Ther* 1989; 248:687-94.
8. Schindl A. Schindl M. Schon H. Knobler R. Havelec L. Schindl L. Low-intensity laser irradiation improves skin circulation in patients with diabetic microangiopathy. *Diabetes Care* 1998; 21:580-4.
9. Lovren F. Triggle CR. Involvement of nitrosothiols, nitric oxide and voltage-gated K⁺ channels in photorelaxation of vascular smooth muscle. *Eur J Pharmacol* 1998; 347:215-21.
10. Reilly ME. Marway JS. Bonner AB. Scott DL. Preedy VR. Does nitric oxide have a role in regulating skeletal muscle protein synthesis? (abstract). *Clin Res* 1997; 92:10.
11. Schini VB. Vanhoutte PM. L-arginine evokes both endothelium-dependent and -independent relaxations in L-arginine-depleted aortas of the rat. *Circ Res* 1991; 68:209-16.
12. Gillardon F. Moll I. Michel S. Benrath J. Weihe E. Zimmermann M. Calcitonin gene-related peptide and nitric oxide are involved in ultraviolet radiation-induced immunosuppression. *Eur J Pharmacol* 1995; 293:395-400.
13. Jia L. Bonaventura C. Bonaventura J. Stamler JS. S-nitrosohaemoglobin: a dynamic activity of blood involved in vascular control. *Nature* 1996; 380:221-6.
14. Hakim TS. Sugimori K. Camporesi EM. Anderson G. Half-life of nitric oxide in aqueous solutions with and without haemoglobin. *Physiol Measurement* 1996; 17:267-77.

CALL FOR PAPERS

Advances in Wound Care is soliciting manuscripts on a variety of topics, including original investigations, clinical reviews, and innovative treatments. For a copy of the Author Guidelines, contact Susan Doan-Johnson, Editor, 800-346-7844, ext.1318; fax: 215-646-0341; or E-mail: susan.doan-johnson@woundcarenet.com. Or consult the journal's Web site, www.woundcarenet.com.